



Gareth Brock

Kate Barker, Christopher J Butterworth and Simon Rogers

Practical Considerations for Treatment of Patients taking Bisphosphonate Medications: An Update

Abstract: Osteonecrosis of the jaw – bisphosphonate-related (ONJ-BR) is an established clinical entity associated with both oral and intravenous (IV) bisphosphonate therapy. An update for the general practitioner on the indications for bisphosphonate therapy and both risk assessment and prevalence of ONJ-BR is provided. Management philosophy within a local unit is illustrated through four brief case studies. It is not uncommon to encounter patients on bisphosphonate therapy in the dental practice environment; the vast majority of these will be on oral bisphosphonates as part of their management for osteoporosis. The risk of developing ONJ-BR is rare in these patients compared with those receiving treatment for skeletal complications associated with cancer, many of whom will be managed with IV bisphosphonates. Although rare, it is important to recognize the potential risk of ONJ-BR. Whilst most patients on oral bisphosphonates can be managed no differently from other patients, it should be appreciated that the relative risk of long-term cumulative exposure, comorbidity and other factors are still to be determined. Surgical intervention and extractions can place the patient at risk of ONJ-BR and vigilance is necessary to ensure that healing progresses satisfactorily. Early referral to the local hospital should be sought if there is cause for concern.

Clinical Relevance: Although the risk of ONJ-BR is low in non-oncological indications, it is important to be aware that it exists and to know how the risk may be minimized.

Dent Update 2011; 38: 313–326

Osteonecrosis of the jaw – bisphosphonate-related (ONJ-BR) is now a well recognized side-effect of bisphosphonate treatment.^{1–7}

Gareth Brock, BDS, BSc(Hons), MFDS RCS(Edin), PhD, Specialist Registrar in Restorative Dentistry, Liverpool Dental Hospital, **Kate Barker**, BDS(Hons), MPhil, MFDS RCSEd, Orthodontic Registrar, The University of Queensland, Australia, **Christopher J Butterworth**, BDS(Hons), MPhil, FDS RCS, FDS(Rest Dent) RCS, Consultant in Oral Rehabilitation, Regional Maxillofacial Unit, Aintree Hospital and Liverpool Dental Hospital and **Simon Rogers**, FDS RCS, FRCS MD, Consultant Oral and Maxillofacial Surgeon, Liverpool University Dental School and Evidence-Based Practice Research Centre (EPRC), Faculty of Health, Edge Hill University, St Helens Road, Ormskirk, L39 4QP, UK.

Bisphosphonates are a commonly prescribed medication; delivery via oral preparations (generally for long-term management of osteoporosis) is associated with a low incidence of ONJ-BR (typically reported as between 1 in 10,000 to 1 in 100,000 patients). Intravenous bisphosphonates, although much more likely to cause ONJ-BR (1 in 10 to 1 in 100 patients), are much less commonly used and tend to be prescribed in an oncology setting. ONJ-BR adversely affects the quality of life and produces significant morbidity in affected patients.⁸ There is an incomplete understanding of associated risk factors for developing ONJ-BR; furthermore, the cumulative effect of long-term oral bisphosphonate therapy, that is now prescribed for a large number of patients, is a concern. In a previous paper,⁹ we discussed the pharmacology of bisphosphonate medications, their

role in the aetiology of ONJ-BR and its clinical presentation, as well as introducing methods of prevention and treatment. Since that paper was published, there have been numerous articles and the most salient of these will serve as an update in this article. This paper will present the most recent data on the indications, incidence, risk factors, prevention of ONJ-BR and the role of the general dental practitioner. The article should serve to help put the risk of ONJ-BR in perspective and help to reassure the clinician that it is an infrequent complication in those patients taking oral bisphosphonates. Four case scenarios have been included to illustrate some of the management issues. The paper focuses on the GDP's role in the prevention of ONJ-BR and does not address the management of established ONJ-BR as this has been already briefly discussed in the earlier article and is the subject of a further update.¹⁰

Bisphosphonates: Common Indications
Osteoporosis prevention and treatment in postmenopausal females
To increase bone mass in male osteoporosis
Prevention and treatment of steroid-induced osteoporosis
Treatment of hypercalcaemia of malignancy
To limit bone metastases of certain tumours
To limit osteolytic lesions of multiple myeloma
To limit Paget's disease of bone

Table 1. Common indications for bisphosphonates.

Generic name	Trade name	Clinical indication
Oral bisphosphonates 1. Alendronate* 2. Risedronate* 3. Etidronate 4. Ibandronate* 5. Clodronate 6. Tiludronate	<i>Fosamax</i> <i>Actonel</i> <i>Didronel</i> <i>Bondronat, Bonviva</i> <i>Bonefos, Loron, Clasteon</i> <i>Skelid</i>	Treatment of osteoporosis and corticosteroid-induced osteoporosis, Paget's disease.
Intravenous bisphosphonates 1. Pamidronate* 2. Zoledronate* 3. Clodronate 4. Ibandronate*	<i>Aredia</i> <i>Zometa, Aclasta</i> <i>Bonefos, Loron, Clasteon</i> <i>Bondronat, Bonviva</i>	Hypercalcaemia of malignancy, osteolytic lesions, Paget's disease, skeletal metastases, osteoporosis (at lower frequency and dose).
*Nitrogen-containing, higher potency bisphosphonates NB Two compounds can be administered orally or intravenously.		

Table 2. Bisphosphonate preparations by name.

Indications for the use of bisphosphonates

Bisphosphonates are frequently prescribed, with alendronate being the 43rd most prescribed drug in the United States in 2009, with a greater number of prescriptions written than for omeprazole or Viagra.¹¹ They are most commonly indicated in the management of osteoporosis,¹² but also have therapeutic benefit in the control of skeletal complications and bony metastases in malignancies such as multiple myeloma and breast cancer. Infrequent indications include Paget's disease, ankylosing spondylitis and osteogenesis imperfecta (Table 1). Continuous bisphosphonate administration appears to result in a staged change in

bone physiology from health to an end-stage necrosis, although the rate at which this develops varies dramatically with site, pharmacodynamics and pharmacokinetics.

The various types of bisphosphonate (Table 2) can lead to confusion amongst patients and clinicians. Although there are differences in potency, bone affinity and mode of action, the critical issue until recently has been regarded as whether the bisphosphonate is administered orally or intravenously. This is based on the logic that IV bisphosphonates are significantly more potent, given at higher doses, and are therefore associated with a much greater likelihood of ONJ-BR. However, drug manufacturers are continually refining administration methods and the advent,

since our last update, of intravenously administered high potency bisphosphonates at significantly lower doses (than doses required for the management of malignancy), for the treatment of osteoporosis has somewhat confused the previously accepted dichotomy. For example, a single, annual IV administration of 5 mg zoledronic acid for patients diagnosed with osteoporosis is in contrast with the same drug being infused in 4 mg doses at 3-weekly intervals for the management of bone metastases. Evidence is emerging to suggest that tailored high potency yet low dose, low frequency IV regimens for osteoporosis have similar reduced risks to lower potency oral preparations.¹³ A general practitioner's initial assessment of a patient with regard to risk for ONJ-BR should therefore be based on the condition that the patient is taking a bisphosphonate for, with oncology patients being considered as high risk.¹⁴

Definition

Patients may be considered to have ONJ-BR if there is:

- Exposed/necrotic bone in the maxillofacial region that has persisted for more than 8 weeks;
- No history of radiation therapy to the jaws; and
- Current or previous treatment with a bisphosphonate.

Patients at risk for ONJ-BR or with established ONJ-BR can also present with other common clinical conditions not to be confused with ONJ-BR. Commonly misdiagnosed conditions may include, but are not limited to, alveolar osteitis (dry socket), sinusitis, gingivitis/periodontitis, caries, periapical pathology and temporomandibular joint disorders.⁶

Incidence

Since our last paper, there have been several publications providing further incidence data for ONJ-BR.¹⁵⁻¹⁹

Under-reporting and a large number of unconfirmed (yet reported) cases have confused these data, although the clear consensus is that patients under treatment with oral bisphosphonate therapy are at a considerably lower risk for ONJ-BR than oncology patients treated with monthly IV bisphosphonates. The incidence of ONJ-

BR from recent Australian surveillance data estimated a risk of 0.01–0.04% for those patients on weekly oral alendronate medication for osteoporosis,¹⁵ whereas an institutional study from a cohort of patients at the University of Southern California School of Dentistry (that appears at present as an outlier) reports an incidence following dental extractions of 4%.¹⁹ One factor that is not fully elucidated in the United States study is the influence that comorbidities such as corticosteroid therapy may have on the risk of ONJ-BR development. Nevertheless, these figures may prove to be more accurate than earlier lower estimates as practitioners' awareness of the condition is raised, patient compliance improves with weekly oral dosing, and longer term follow-up of patient cohorts is reported. There is emerging evidence, for example, that a cumulative dose effect is present and therefore duration of oral therapy exceeding two to three years may increase the risk of developing ONJ-BR.^{6,15} Importantly, the calculated frequency from the Australian data increased by up to a factor of seven when dental extractions were carried out, indicating that an awareness of patients' current medication is crucial as oral bisphosphonates for osteoporosis are commonly used and, although ONJ-BR remains a rare complication, vigilance is necessary to ensure that appropriately informed pre-operative consent is provided and that healing progresses satisfactorily following an extraction or surgical procedure.

Estimates of the cumulative incidence of ONJ-BR for patients receiving IV medication range from 0.8–12%,⁶ although the sample sizes, comorbidities, interventions (such as extractions) and awareness factors as for oral bisphosphonate administration provide for this wide distribution. Nevertheless, the overwhelming evidence is that risk is significantly greater for these patients who, until recently, have been on IV therapy for hypercalcaemia of malignancy, bony metastases and multiple myeloma. As discussed above, novel administration regimens for osteoporosis with IV bisphosphonates at low frequency and dose appear to be associated with a lower risk that may be comparable with lower potency oral preparations, although to date it is too early for data analysis. The reason for this reduced risk is assumed to be related to the effective systemic drug dose that is delivered (dependent on dose, potency, frequency of

administration and bioavailability) rather than simply its potency.²⁰

There are very little data from patients in the UK, although a recent survey of consultant oral and maxillofacial surgeons reported that nearly two-thirds had seen new cases of ONJ-BR from IV bisphosphonates in the last year, with one-quarter having seen three or more cases.²¹

Risk factors

The aetiology of ONJ-BR is multifactorial. Several risk factors have been recognized,^{6,7,8,16,17} to date there is no formal consensus to risk stratification, although management algorithms have been proposed and doubtlessly will be refined as the clinical and biological knowledge base improves.¹⁴ This is important if we are to identify and advise 'at risk' patients effectively. Future research will help quantify the relative risks and a new, prospective case cohort series linked with national registration would be very useful. The recently updated position paper published by the American Association of Oral and Maxillofacial Surgeons lists drug-related factors, local factors, systemic factors, genetic factors and preventive factors as key themes;⁶ the following comments provide updated information from a number of sources.

Drug-related factors

Potency of bisphosphonate medication

It is often said that the reason for a higher incidence of ONJ-BR is related to the higher potency of the drug. For example, the IV bisphosphonate zoledronate is approximately 1,000 times more potent than alendronate (for oral administration). However, the relative potency of oral alendronate is greater than (approximately twice) that of IV pamidronate. The lower incidence of ONJ-BR from oral bisphosphonates therefore not only relates to their relative potency, but more specifically to their relative effective systemic dose (that is dependent on potency, dose frequency, amount administered and bioavailability). The low effective systemic dose from oral administration is primarily due to the low lipophilicity of bisphosphonates which limits their absorption. Nevertheless, bioavailability can be increased by the concomitant administration of certain

drugs – intravenous H2 receptor blockers, such as ranitidine, for example, increase certain oral bisphosphonates' bioavailability by 20–100%, and over-the-counter oral H2 receptor blockers may have a similar effect. This may be particularly important given that patients often self-medicate for oesophagitis, a common side-effect of oral bisphosphonate use.²⁰

Local risk factors

Dento-alveolar surgery

Extractions, implant placement, periodontal surgery involving osseous modification and periapical surgery have all been associated with an increased risk of developing ONJ-BR.⁶ Cancer patients receiving IV bisphosphonates and undergoing dento-alveolar surgery are at least seven times more likely to develop ONJ-BR than those who do not undergo such procedures.⁶ In the University of Southern California School of Dentistry research discussed earlier, almost 50% of those patients who developed ONJ-BR did so at the extraction site,¹⁹ whilst the recently published Australian data discussed previously reported a seven times greater frequency of ONJ-BR in all patients on bisphosphonates, following extractions.¹⁵

Local anatomy

Reported cases suggest that the mandible is at least twice as likely to be affected as the maxilla.^{6,8} The risk of developing ONJ-BR following extraction of a mandibular molar could therefore be considered greater than that of a maxillary incisor within the same patient. ONJ-BR is also more common in areas with thin mucosa overlying a bony prominence, such as tori and mylohyoid ridges, although no data is currently available to provide risk estimates.⁶

Oral disease

Patients with inflammatory dental disease (for example, periodontal and dental abscesses) and exposed to IV bisphosphonates are reported to be seven times more likely to develop ONJ-BR.⁶ Interestingly, however, several studies have not been able to establish an association between CPITN scores and ONJ-BR.²²

Drug-related effects

Drug-related effects of direct toxicity of bisphosphonates on oral epithelium have also been reported as a potentially significant aetiological factor.²³ An evidence-based hypothesis for impairment of molecular signalling not only of osteoblasts and osteoclasts, but also of fibroblasts and keratinocytes, causing failure in multiplication and migration and consequent defective mucosal wound healing has also been proposed.²⁴

Systemic risk factors

Smoking has been reported as a risk factor for the development of ONJ-BR, however, no increased risk associated with alcohol has been demonstrated. The association with smoking is thought to be due to its adverse effects on wound healing, which may well compound the deleterious effects that bisphosphonates have on oral epithelium.^{24,25} Furthermore, there is no statistically significant association between risk for ONJ-BR and malignancy type.²⁶

Other systemic factors, for example, poorly controlled diabetes and obesity have been reported to increase the risk for ONJ-BR.⁶

Concomitant corticosteroid therapy is emerging as a significant co-risk factor in the development of ONJ-BR.¹⁴ A key side-effect of prolonged corticosteroid therapy in addition to immunosuppression is a general osteoporosis – many patients on significant long term doses of corticosteroids are therefore concurrently on bisphosphonate therapy for skeletal protection. Corticosteroids themselves are associated with osteonecrosis, particularly of the hip, knee, shoulder and ankle – although there has been no specific link to date with alveolar bone. Nevertheless, various molecular mechanisms of corticosteroid-induced osteonecrosis have been described and there is also a recognized increased bioavailability of alendronate with concurrent prednisone use.²⁰ It is possible, therefore, that the risk of developing ONJ-BR will be increased in those patients receiving prolonged concurrent corticosteroid medication.

Genetic factors

Single nucleotide changes in the cytochrome P450-2C gene have been

associated with an increased risk of ONJ-BR among multiple myeloma patients treated with IV bisphosphonates.²⁷

Preventive factors

There has been significant confusion interpreting the terminal half-lives of bisphosphonates.²⁰ At the time of our previous *Dental Update* article, it was assumed that the terminal half lives of all bisphosphonates were in figures of years. However, drug elimination appears to be more complex – in particular, multiphasic. The half-lives of all bisphosphonates appear to be long owing to the sequestered drug gradually leaving from slow bone turnover areas, probably as a slow, progressive ‘trickle effect’ after drug discontinuation. There also appears to be a more rapid elimination phase (ie shorter half life) from areas of more rapid bone turnover, seen in shorter-term drug studies. The concept of a ‘drug holiday’ may therefore be beneficial in areas of high bone turnover, such as the maxilla and mandible, thus reducing the risk of developing ONJ-BR. Estimates suggest that bisphosphonate discontinuity of several months will eliminate more than 90% of the drug within these areas.²⁰ One must, of course, weigh up the risks of drug cessation versus the benefits of elective oral surgery, which will be unique to each patient.

A similar concept may also be applied to a reduction or cessation in corticosteroid therapy – certainly, if a patient is due to reduce his/her steroid therapy, delaying oral surgery should be considered.

Many of the preventive strategies mentioned require reliable markers of local bone turnover to quantify their benefit, although to date this has proved difficult and evidence is therefore empirical.

Prevention of ONJ-BR

Management of patients with established ONJ-BR is difficult as a cure is unlikely and options for management are limited. Therefore, prevention of ONJ-BR is the mainstay of existing management. Currently, there is lack of clarity on how best to prevent and manage ONJ-BR. Guidelines are based on clinical experience and those established for prevention of osteoradionecrosis, as randomized controlled studies and substantial observational studies,

are lacking.^{1,6,8,9} Knowledge regarding key risk factors and confounding variables is also limited, such that these guidelines require a pragmatic approach and will be reviewed and altered in the light of ongoing patient care and experience and an increasing body of published literature.

Increased awareness on the part of the oncologist, dentist and patient is an important aspect in the prevention of ONJ-BR. Patients need to be informed by the treating oncologist prior to commencement of IV treatment about the risk of ONJ-BR. In a recent survey, only 41% of haematologists/ oncologists always warned patients of the risk of ONJ-BR before commencing with IV bisphosphonate medications,²⁸ although best practice would suggest that, as a minimum, all patients, before beginning IV bisphosphonates, have timely access to dental treatment. For patients that do not have a general dental practitioner, alternative arrangements should be made for them to be seen either in the primary care sector, in the community setting, or through cancer networks as a matter of urgency.

Patients with osteoporosis and other non-malignant bone conditions who have been taking oral bisphosphonate therapy for many years should be made aware of the low risk of developing ONJ-BR following an ‘invasive’ dental procedure, such as an extraction, and should be encouraged to see their dentist for regular check-ups. The risk of developing ONJ-BR associated with oral medications appears to be due to cumulative exposure; therefore, dental assessment prior to commencement of oral medication is not necessary and routine dental treatment should not be altered or delayed.⁸

The issue of antibiotic cover is contentious; currently there are no controlled studies to support surgical antibiotic prophylaxis for invasive dental procedures in bisphosphonate patients. Considering the paucity of evidence, the low incidence of ONJ-BR in patients being treated for osteoporosis and the potential reaction to antibiotics, the authors do not recommend routine use of antibiotic prophylaxis in this group of patients.

Those patients receiving IV bisphosphonates may, however, benefit from antibiotic prophylaxis prior to treatment. A recent survey of British oral and maxillofacial surgeons found that there was considerable

variation in management of these patients. A questionnaire was mailed to 322 consultants working at 154 hospitals in the summer of 2008. There was a 57% response rate with at least one consultant responding from 72% (111/154) of hospitals. Screening patients prior to starting IV bisphosphonates was uncommon (15%) and relatively few would stop bisphosphonate administration. Almost all consultants would prescribe antibiotics for molar extractions, two-thirds of whom would provide this both pre- and post-extraction.²¹

If antibiotic prophylaxis is to be considered, it is important that a suitable antibiotic is administered. Current recommendations indicate that penicillin V may be the most applicable antibiotic to administer, with doxycycline or metronidazole use for penicillin-allergic patients.^{6,14}

Patient management advice

In dental practice, all patients should be queried about conditions for which bisphosphonates are commonly prescribed, such as osteoporosis, a history of metastatic cancer to bone, long-term steroid use, multiple myeloma and bone diseases, such as Paget's disease. Dentists are aware that patients frequently do not remember the medications they are taking and this is particularly true for the recent introduction of annual bisphosphonate infusions. As discussed, the dentist must not assume that physicians will have clearly discussed the potential risks of ONJ-BR development prior to medication administration.

Patients not yet receiving bisphosphonate treatment, prior to commencement of IV preparations

Patients should have a thorough dental examination and be rendered dentally fit prior to the commencement of IV bisphosphonate medications. All unrestorable teeth should be removed, all invasive dental procedures should be completed, and management to promote periodontal health instituted. If systemic conditions permit, IV therapy should be delayed to ensure optimal dental health and allow extraction sites to heal (14–21 days).^{7,9} Dentures should be checked to ensure a good fit with careful consideration of their design, as prosthesis-associated

mucosal breakdown is the second most commonly identified risk factor in ONJ-BR development.²⁹ Oral hygiene instruction should be provided, to ensure patients are aware of the need for excellent oral hygiene and the need for regular dental visits. Furthermore, ongoing care should be well orchestrated and patients made fully aware of the present and cumulative risk of ONJ-BR, in addition to warning symptoms such as pain, swelling, exposed bone, altered sensation and increasingly mobile teeth. As future exodontia is a significant risk factor for ONJ-BR, careful thought of teeth that are currently in an acceptable condition but are unlikely to be retained in the long term must be made, possibly with a view to such treatment taking place prior to commencing IV bisphosphonate therapy.

Management of patients on bisphosphonates for osteoporosis

Most patients receiving bisphosphonates for osteoporosis will be taking oral therapy, although there are currently two IV preparations in use (*Aclasta* and *Bonviva*). Whilst the incidence of ONJ-BR is considerably less in this group, the complication of assessing individual risk outlined above on the basis of treatment duration and existing co-morbidities make it more logical to make a patient dentally fit prior to bisphosphonate therapy commencing.

All patients receiving bisphosphonates for osteoporosis, and who require tooth extraction or an oral surgical procedure, should be counselled about the very small risk of osteonecrosis of the jaw associated with bisphosphonate use. This counselling process should be documented in the patient record.

Patients who take bisphosphonates for osteoporosis can be managed in primary care and do not routinely require referral to secondary care. Endodontic management should be considered as appropriate to routine treatment planning and unavoidable extractions should not be delayed. It may, however, be prudent to stage non-urgent surgery, allowing two months between sextants to assess for the development of complications; extraction with minimal trauma is also an accepted standard. Nevertheless, this paper has highlighted

an increased prevalence of ONJ-BR in post-extraction patients; therefore, more high risk procedures should ideally be avoided, with reliance on restorative management including root canal treatment and non-surgical periodontal therapy, all of which can be achieved in a primary care setting.

There is no robust evidence regarding 'drug holidays'; although, if there is evidence of an increased risk for a patient developing ONJ-BR, for example, a prolonged use of oral bisphosphonates over many years in conjunction with corticosteroid medication, liaison with the patient's prescriber regarding a possible 'drug holiday' would seem sensible.

Routine prophylactic and/or postoperative antibiotic therapy is NOT recommended as there is no evidence available that antibiotic prophylaxis reduces the incidence of osteonecrosis of the jaw following extractions or oral surgical procedures. Chlorhexidine mouthwash should, however, be used prior to the extraction/oral surgical procedure.

Patients should be reviewed 3–4 weeks after the procedure to ensure that the socket/surgical site has healed and advised that, if any postoperative problems (pain or unpleasant smell or taste in the mouth) develop sooner, they should return to see the dentist before the planned appointment. If healing has not taken place after 4 weeks, osteonecrosis of the jaw should be suspected and the patient referred to secondary care.

Management of patients on bisphosphonates for conditions related to cancer

For the management of conditions related to cancers, bisphosphonates are usually administered intravenously. However, for certain conditions, oral preparations may be used (*Bondronat*, *Loron*, *Bonefos*). Patients may present in primary care with advice to be dentally assessed and made dentally fit before starting IV bisphosphonate treatment. This assessment and any treatment required should be carried out before the IV bisphosphonate is started, if at all possible (see above).

Patients, who have already received IV bisphosphonate therapy and develop dental problems which might require extractions (or surgical intervention), should be referred to secondary care for assessment and management.

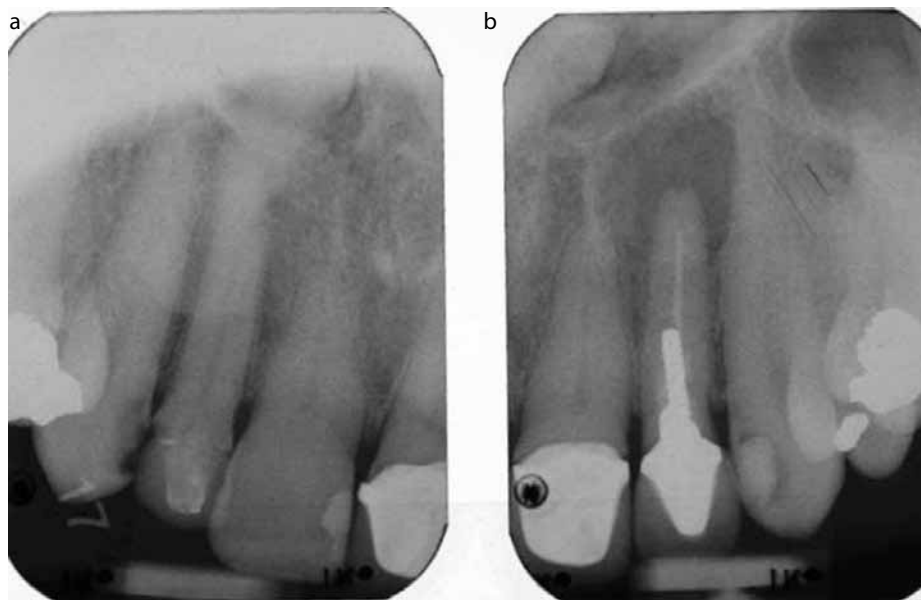


Figure 1. (a, b) Asymptomatic upper left lateral incisor; patient due to begin intravenous bisphosphonate therapy for a skeletal metastasis. Note the associated periradicular radiolucency.

Case studies

Case study 1 (Figure 1)

This patient presented with an asymptomatic upper left lateral incisor. Medical history-taking established that the patient was due to begin IV bisphosphonate therapy for a skeletal metastasis (most commonly from breast or prostate cancer).

Treatment options would therefore be to:

- Leave, with or without subsequent monitoring, given the periapical radiolucency;
- Extract the tooth with adequate time for healing;
- Provide endodontic retreatment – either a retrograde or orthograde approach.

Treatment recommendation

In view of the indications for this patient's impending IV bisphosphonate therapy, the risk of retaining a tooth with periapical pathology outweighed the benefit of attempting retreatment. Following careful discussion and gaining informed consent, the tooth was therefore extracted prior to intravenous bisphosphonate therapy commencing, mucosal healing achieved and a temporary, well-fitting removable prosthesis (with tooth support where feasible) placed with subsequent review of

the restorative options depending on the response to chemotherapy and the patient's preference.

Case study 2 (Figure 2)

A 77-year-old male with osteoporosis, complicated with chronic obstructive airways disease (COAD), began oral bisphosphonate medication six years prior to presentation. His lower right third molar was asymptomatic but carious.

Treatment options were therefore to:

- Leave;
- Plan for surgical extraction;
- Provide root canal treatment (RCT) and subsequent restoration of the tooth.

Treatment recommendation

Unlike Case 1, this patient was taking long-term oral bisphosphonates for osteoporosis rather than management of malignancy. In light of recent reports, his COAD warranted inhaled corticosteroids, the dose and duration of which may also have had a bearing on risk assessment, in conjunction with consideration for the surgical extraction of a mandibular molar. Furthermore, bisphosphonate medication had been provided for significantly longer than recent data, showing an increased

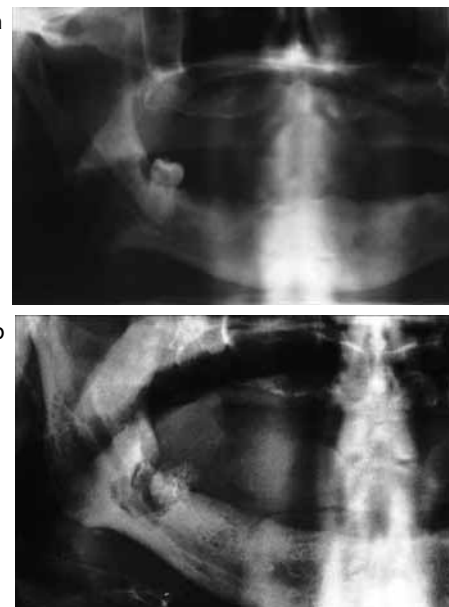


Figure 2. (a) Panoramic radiograph with an asymptomatic lower right third molar; patient had been prescribed oral bisphosphonates for six years prior to presentation. Note a coronal radiolucency in keeping with caries diagnosed clinically. **(b)** Follow-up panoramic radiograph with Whitehead's varnish pack *in situ*, used primarily in this case for its marked anaesthetic action. Note the attendant focal demineralization of the bone, often a later stage in the progression of ONJ-BR.

incidence of ONJ-BR beyond two years' administration.¹¹ There was therefore considerable concern about the potential for ONJ-BR development following extraction.

RCT and restoration, or a 'drug holiday' (cessation of the oral bisphosphonate for 2–3 months in consultation with the patient's physician) followed by surgical extraction with antibiotic cover were the two most contemporaneous options in light of current evidence. Oral bisphosphonate medication could then have been resumed once healing was complete. Access difficulty for root canal therapy ruled this more conservative option out. Unfortunately, this patient underwent a surgical extraction in mid-2005 without stopping medication or being given antibiotic cover, and subsequently developed intractable ONJ-BR.

Case study 3 (Figure 3)

A 63-year-old, partially dentate female prescribed IV bisphosphonates for

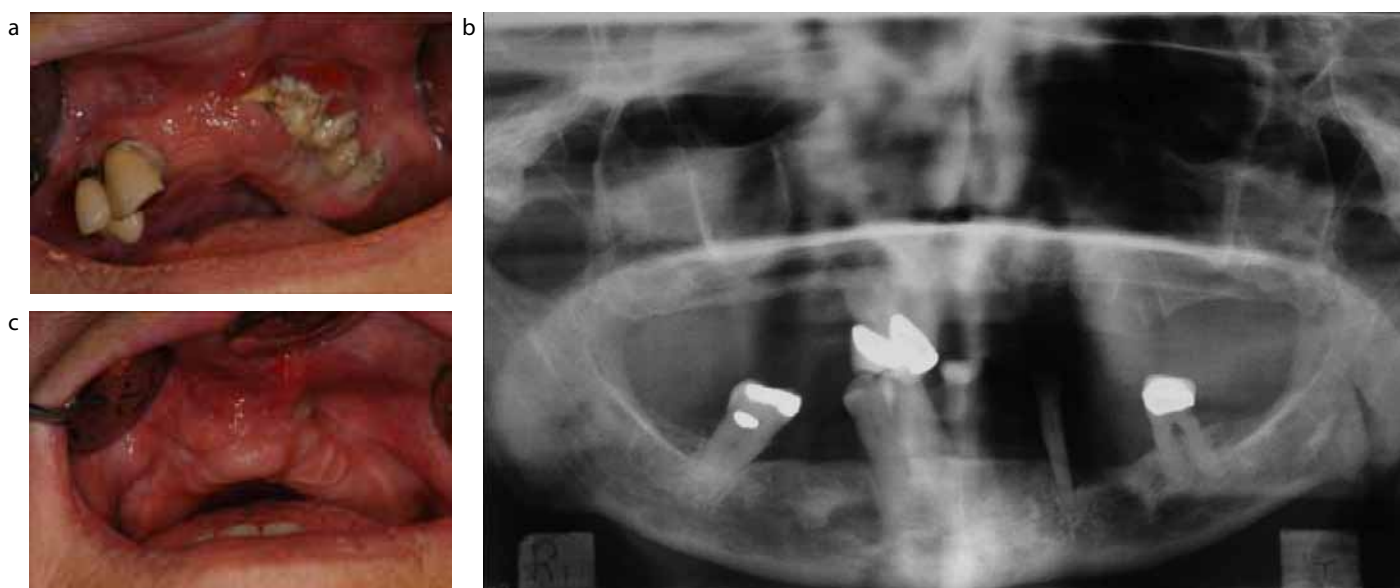


Figure 3. (a) Intra-oral view at presentation; patient prescribed intravenous bisphosphonate medication for previous 3 years with generalized discomfort from her mobile, periodontally involved maxillary teeth. (b) Panoramic radiograph at presentation. (c) Approximately twelve months following presentation and subsequent exfoliation of the remaining maxillary teeth, mucosal healing was almost complete.

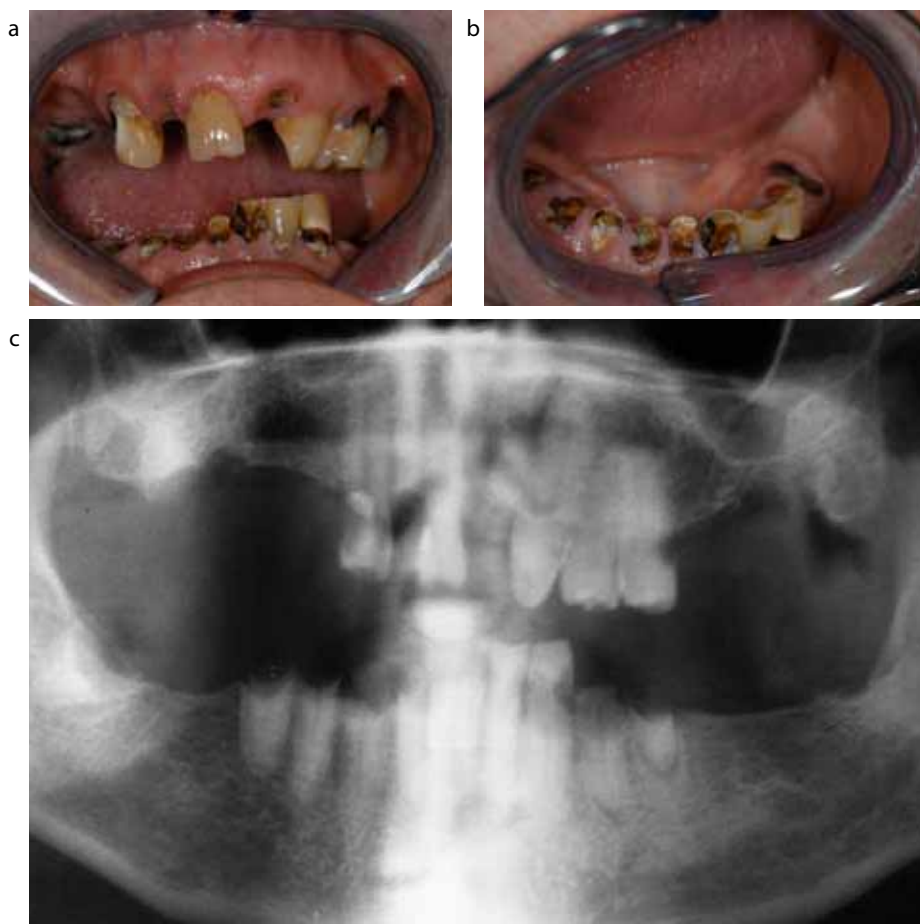


Figure 4. (a, b) A case of dental neglect in a 70-year-old gentleman who was asymptomatic at presentation. (c) Panoramic radiograph taken at presentation shows gross caries and periapical radiolucencies associated with a number of teeth. (d) Unfortunately this gentleman developed ONJ-BR following careful extraction of the upper right canine, although the socket of the lower right premolar (extracted at the same appointment) healed uneventfully.

multiple myeloma, presented complaining of generalized discomfort from her mobile, periodontally involved maxillary teeth. At presentation, bisphosphonate infusions had been administered for approximately 3 years.

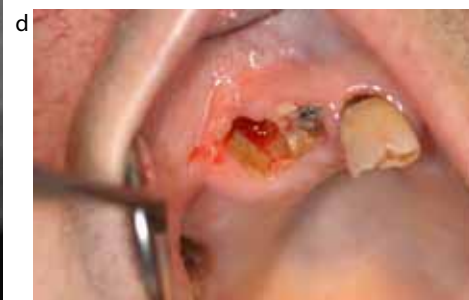Treatment options were therefore

to:

- Leave, monitor and allow the teeth to exfoliate spontaneously;
- Extract her teeth with antibiotic prophylaxis.

Treatment recommendation

Given the indications for this patient's IV bisphosphonate therapy,



discussion with, or referral to the local maxillofacial/oral surgery department would be prudent if this scenario presented in general practice; cessation of therapy is also extremely unlikely.

Following careful discussion of the risks and benefits of each option, this patient's preference was to allow the upper teeth to exfoliate naturally; mucosal healing was complete approximately 12 months later. A complete denture with maximum mucosal support and a resilient lining was subsequently constructed. This conservative approach seemed prudent, although high risk in that any acute pain or swelling may have necessitated extractions. The panoramic radiograph hints at the potential risk with extractions – note the anticipated bone fill of previous left maxillary extraction sockets that has not taken place and a thickened lamina dura outlining the same sites.

Case study 4 (Figure 4)

A 70-year-old gentleman presented to our Oral Surgery department in 2006 with generalized dental neglect. He had completed chemotherapy for myeloma in 2004 and had been prescribed monthly Zoledronate infusions for over five years prior to presentation. In 2006, he was asymptomatic; although radical intervention to secure oral health would have been the usual course of events, this patient's myeloma history and, in particular, his long-term prescription of high potency intravenous bisphosphonates made this plan extremely high risk. Following discussion of the risks and benefits of possible treatment, it was agreed to adopt a conservative management approach with no active intervention other than treatment of symptomatic teeth when necessary.

In 2010, extractions of the upper right canine and lower right first premolar proved necessary. Peri-operative antibiotic cover was provided in conjunction with chlorhexidine mouthwash. Whilst the mandibular extraction site healed successfully, the upper right canine socket showed no evidence of epithelialization eight weeks post-extraction, and a diagnosis of ONJ-BR was made (Figure 4d). Fortunately, the patient remains asymptomatic and is therefore being managed conservatively with twice daily chlorhexidine mouthwashes at present.

Conclusion

As prescription of both IV and oral bisphosphonates increases, the general dental practitioner is more likely to encounter patients taking these medications. The above contemporaneous advice will be reviewed as more research data and clinical experience is forthcoming. As the mainstay of treatment is currently prevention, it is important that protocols are implemented in dental practices to minimize the risk of ONJ-BR. Routine dental care, including tailored oral hygiene advice, non-surgical periodontal therapy and orthograde endodontics should be considered the mainstay of prevention in a primary care setting, in addition to conventional fixed and removable prosthodontics, where appropriate. Elective surgical procedures should be subjected to risk-benefit assessment on an individual basis, with referral for advice or treatment where appropriate.

References

1. Arrain Y, Masud T. Recent recommendations on bisphosphonate-associated osteonecrosis of the jaw. *Dent Update* 2008; **35**: 238–242.
2. Abu-Id MH, Warnke PH, Gottschalk J, Springer I, Wiltfang J, Acil Y *et al*. "Bis-phossy jaws" – high and low risk factors for bisphosphonate-induced osteonecrosis of the jaw. *J Cranio-maxillofac Surg* 2008; **36**: 95–103.
3. Grewal VS, Fayans EP. Bisphosphonate-associated osteonecrosis. A clinician's reference to patient management. *N Y State Dent J* 2008; **74**: 38–44.
4. Ruggiero SL, Mehrorta B. Bisphosphonate-related osteonecrosis of the jaw: diagnosis, prevention and management. *Ann Rev Med* 2009; **60**: 85–96.
5. Silverman SL, Landesberg R. Osteonecrosis of the jaw and the role of bisphosphonates: a critical review. *Am J Med* 2009; **122**: S33–S45.
6. American Association of Oral and Maxillofacial Surgeons position paper on bisphosphonate-related osteonecrosis of the jaws – 2009 Update. Advisory Task Force on Bisphosphonate-Related Osteonecrosis of the Jaws. *J Oral Maxillofac Surg* 2009; **67**: 2–12, Suppl 1.
7. Novince CM, Ward BB, McCauley LK. Osteonecrosis of the jaw: an update and review of recommendations. *Cells Tissues Organs* 2009; **189**: 275–283.
8. Marx RE, Sawatari Y, Fortin M, Broumand V. Bisphosphonate-induced exposed bone (osteonecrosis/osteopetrosis) of the jaws: risk factors, recognition, prevention, and treatment. *J Oral Maxillofac Surg* 2005; **63**: 1567–1575.
9. Barker KE, Rogers SN. Bisphosphonate-associated osteonecrosis of the jaws: a guide for the general dental practitioner. *Dent Update* 2006; **33**: 270–275.
10. McLeod NMH, Patel V, Kusanale A, Rogers SN, Brennan PA. Bisphosphonate osteonecrosis of the jaw: a literature review of UK policies on the management of bisphosphonate osteonecrosis of the jaw. *Br J Oral Maxillofac Surg* 2010; Epub ahead of print.
11. www.pharmacytimes.com/media/pdf/PHTM_36.pdf accessed 2 Jan 2011.
12. NICE Technology Appraisal Guidance 161. Alendronate, etidronate, risedronate, raloxifene, strontium ranelate and teriparatide for the secondary prevention of osteoporotic fragility fractures in postmenopausal women. October 2008.
13. Black DM, Delmas PD, Eastell R, Reid IR, Boonen S, Cauley JA *et al*. HORIZON Pivotal Fracture Trial: Once-yearly zoledronic acid for treatment of postmenopausal osteoporosis. *N Engl J Med* 2007; **356**: 1809–1822.
14. Malden N, Beltes C, Lopes V. Dental extractions and bisphosphonates: the assessment, consent and management, a proposed algorithm. *Br Dent J* 2009; **206**: 93–98.
15. Mavrokokki T, Cheng A, Stein B, Goss A. Nature and frequency of bisphosphonate-associated osteonecrosis of the jaws in Australia. *J Oral Maxillofac Surg* 2007; **65**: 415–423.
16. American Association of Oral and Maxillofacial Surgeons position paper on bisphosphonate-related osteonecrosis of the jaws. *J Oral Maxillofac Surg* 2007; **65**: 369–376.
17. Khosla S, Burr D, Cauley J. Bisphosphonate-associated

- osteonecrosis of the jaw: report of a task force of the American Society for Bone and Mineral Research. *J Bone Miner Res* 2007; **22**: 1479–1491.
18. Hoff AO, Toth BB, Altundag K, Johnson MM, Warneke CL, Hu M *et al*. Frequency and risk factors associated with osteonecrosis of the jaw in cancer patients treated with intravenous bisphosphonates. *J Bone Miner Res* 2008; **23**: 826–836.
 19. Sedghizadeh PP, Stanley K, Caligiuri M, Hofkes S, Lowry B, Shuler CF. Oral bisphosphonate use and the prevalence of osteonecrosis of the jaw: an institutional inquiry. *J Am Dent Assoc* 2009; **140**: 61–66.
 20. Zairowski J. Comment on the American Association of Oral and Maxillofacial Surgeons statement on bisphosphonates. *J Oral Maxillofac Surg* 2007; **65**: 1440–1441.
 21. Rogers SN, Hung J, Barber AJ, Lowe D. A survey of consultant members of the British Association of Oral and Maxillofacial Surgeons regarding bisphosphonate-induced osteonecrosis of the jaws. *Br J Oral Maxillofac Surg* 2009; **47**: 598–601.
 22. Kyrgidis A, Vaihtsevanos K. Risk factors for bisphosphonate-related osteonecrosis of the jaws. *J Oral Maxillofac Surg* 2009; **67**: 2553–2554.
 23. Reid IR, Bolland MJ, Grey AB. Is bisphosphonate-associated osteonecrosis of the jaw caused by soft tissue toxicity? *Bone* 2007; **41**: 318–320.
 24. Kyrgidis A, Triaridis S, Antoniadis K. Effects of bisphosphonates on keratinocytes and fibroblasts having a role in the development of osteonecrosis of the jaw. *Biosci Hypotheses* 2009; **2**: 153–159.
 25. Meechan JG, Macgregor ID, Rogers SN, Hobson RS, Bate JPC, Dennison M. The effect of smoking on immediate post-extraction socket filling with blood and on the incidence of painful socket. *Br J Oral Maxillofac Surg* 1988; **26**: 402–409.
 26. Wessel JH, Dodson TB, Zavras AI. Zoledronate, smoking and obesity are strong risk factors for osteonecrosis of the jaw: a case-control study. *J Oral Maxillofac Surg* 2008; **66**: 625–631.
 27. Sarasquete ME, Garcia-Sanz R, Marin L, Alcoceba M, Chillon MC, Balanzategui A *et al*. Bisphosphonate-related osteonecrosis of the jaw is associated with polymorphisms of the cytochrome P450 CYP2C8 in multiple myeloma: a genome-wide single nucleotide polymorphism analysis. *Blood* 2008; **112**: 2709–2712.
 28. Barker K, Lowe D, Olujohungbe A, Low E, Rogers SN. Survey of members of myeloma UK on bisphosphonates-associated jaw osteonecrosis. *Br J Haematol* 2007; **139**: 626–628.
 29. Kyrgidis A, Vaihtsevanos K, Koloutsos G *et al*. Bisphosphonate related osteonecrosis of the jaws: a case-control study of risk factors in breast cancer patients. *J Clin Oncol* 2008; **26**: 4634–4638.